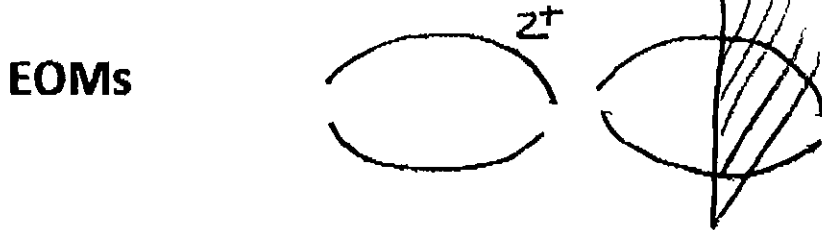
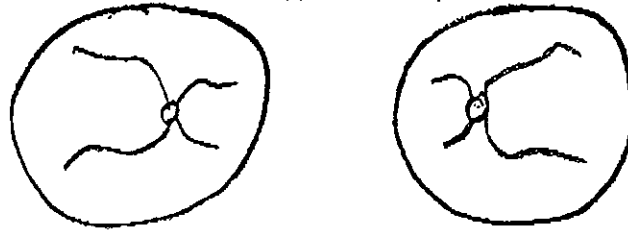


# What's with the Hieroglyphics and Alphabet Soup on an Eye Consult????

Monday  
12-14-09  
NRC Handout  
By  
Dr. Levin  
(4 pages)

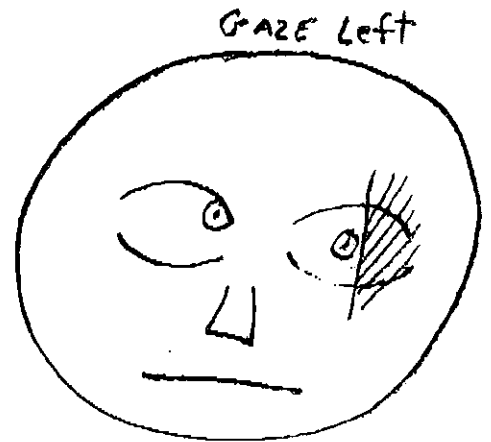**V** Vision(distance) < <sup>Right</sup> < <sup>Left</sup> **V** <sup>20/20</sup> / <sup>20/20</sup> **N**(near)  
**P** Pupils **P** < <sup>4</sup> → <sup>2</sup> / <sup>4</sup> → <sup>2</sup> 4mm constricts to 2mm with light  
**Ta** <sup>8:00 AM</sup> **K** <sup>18</sup> / <sup>18</sup> **Applanation** Pressures(tenometry) Time taken  
(normal 12-22 mmHg)

**DFE** Dilated Fundus exam (tropicamide/phenylephrine)  
c/d cup/disc ratio (normal 0.1 - 0.4)



**Strabismus**

5	12	18
5	10	20
8	6	20



2

**"I have 1 minute to spend on an Eye exam. What should I do?????"**

**-Review the Vision**

Vision What is normal?

Infant Fixes and follows

Child age 3 20/40 no more than 1 line difference

age 5 20/20

Can they recognize objects they are being tested with?

Encouragement (bribery) with stickers

Use of a near card

**Auto screeners**

**Advantages**

Less space needed

Less interruption with sibling help

**Disadvantages**

Expense

Intimidating

**-Check the Pupils**

Anisocoria (unequality) Should I worry?

Physiological - 8% -20% of population

Post-traumatic/Iritis

Horners congenital vs acquired (neuroblastoma)

3<sup>rd</sup> CN Palsy congenital, post traumatic

**-EOMs/Confrontational fields**

Don't forget convergence -- patients with headaches with reading



## **-Fundus Examination**

**Right eye examines right eye**

**Left eye examines left eye**

**Everyone with headaches -- view and document presence or absence of optic nerve swelling**

**Idiopathic Intracranial hypertension**

**Headaches, visual obscurations pulsatile tinnitus**

**(new medications, BCP, vitamins, steroids antibiotics obesity)**

## **"My childs eye crosses"**

## **-Strabismus Evaluation**

**Cover test vs Hirschberg corneal light reflex**

**Cover Uncover Test**

**ET - Esotropia - going in**

**Alternate Cover Test**

**XT - Exotropia - going out**

**LHT/RHT - left/right hypertropia**

**Infantile Esotropia(<6months 100% surgery,)**

**Accomodative Esotropia(1-3years age 100% glasses, 25% also surgery)**

**Summary - the one minute eye test**

**Review vision(amblyopia, glasses, more ominous)**

**Pupils(Horner's, idiopathic, 3<sup>rd</sup> CNP)**

**EOMs/Confrontational visual fields(muscle palsies)**

**Cover Test(strabismus)**

**Fundi/ Red reflex(infants/young children) tumors, cataracts, retinal detachment**

**Tearing**- Painful or not

Painful \_\_\_\_\_ No Pain

Trichiasis Nasolacrimal duct obstruction

Foreign Body Glaucoma - photophobia

Viral Keratitis

NLD Obstruction – punctual or distal etiology

Massage until 1 year then to OR to probe

After 18 months age placement of tubes

**The Red Eye** (What is the vision?) (Is it Painful?)

Conjunctivitis (<6yrs)**Bacterial** – yellow/green d/c Vigamox

(6-12yrs)**Viral** – watery, +/- painful, no tx, ?Viroptic(HSV)

**Allergic** – itchy, mast cell stabilizer Pataday

Uveitis photosensitive(pain), no discharge, decreased vision

Corneal abrasions, foreign bodies,

More ominous- retinal detachment, tumors)

**Headaches**

Family history, frequency, **activities** that elicit onset, **onset**

Remember: Idiopathic Elevated Intracranial Hypertension - document nerves

Pupils, visual fields

**Is my child Blind?**

2 month old – no evidence of vision

Pupils, nystagmus, red reflex(optic nerve hypoplasia, Leber’s

DVM(delayed visual maturation)